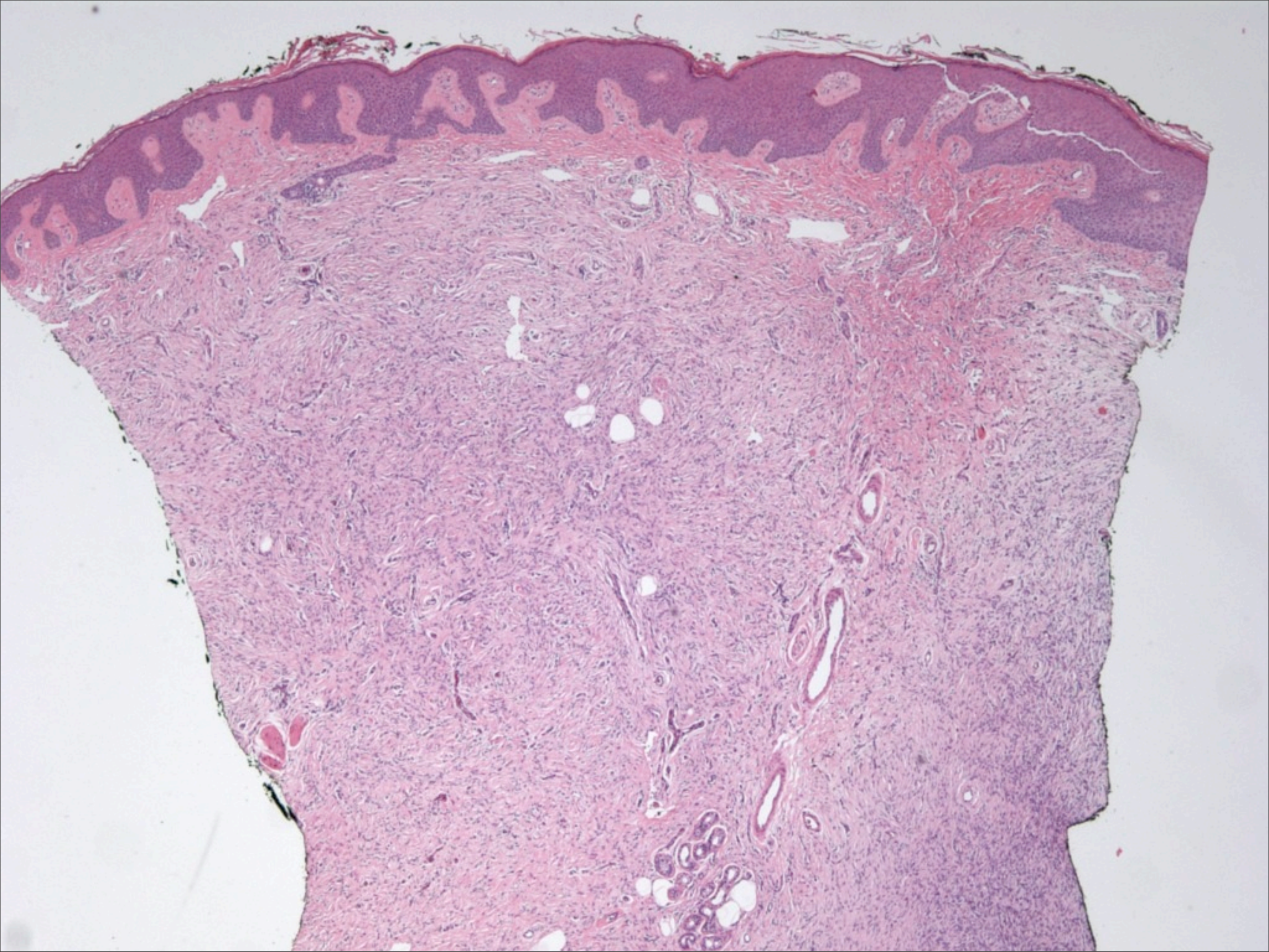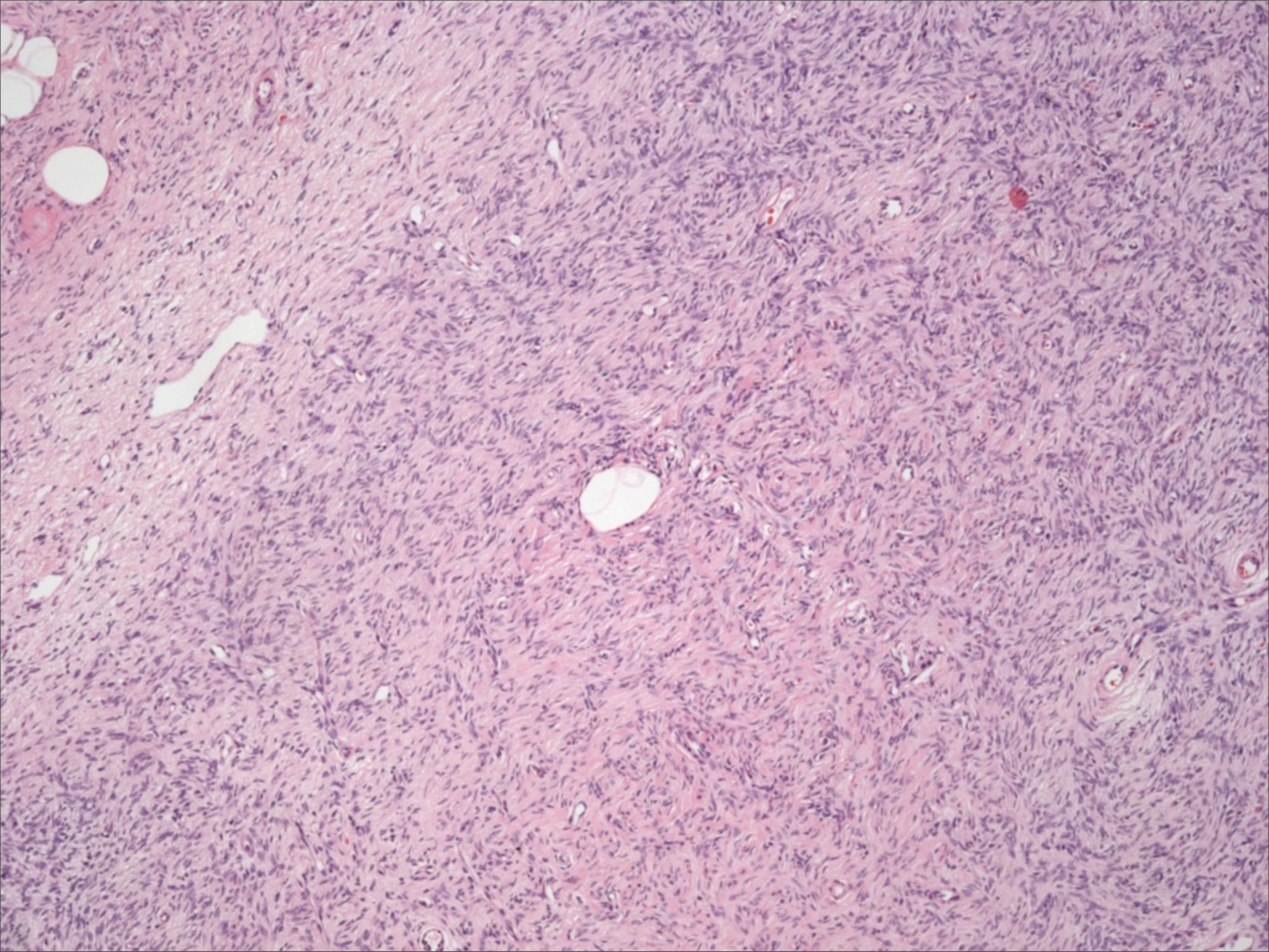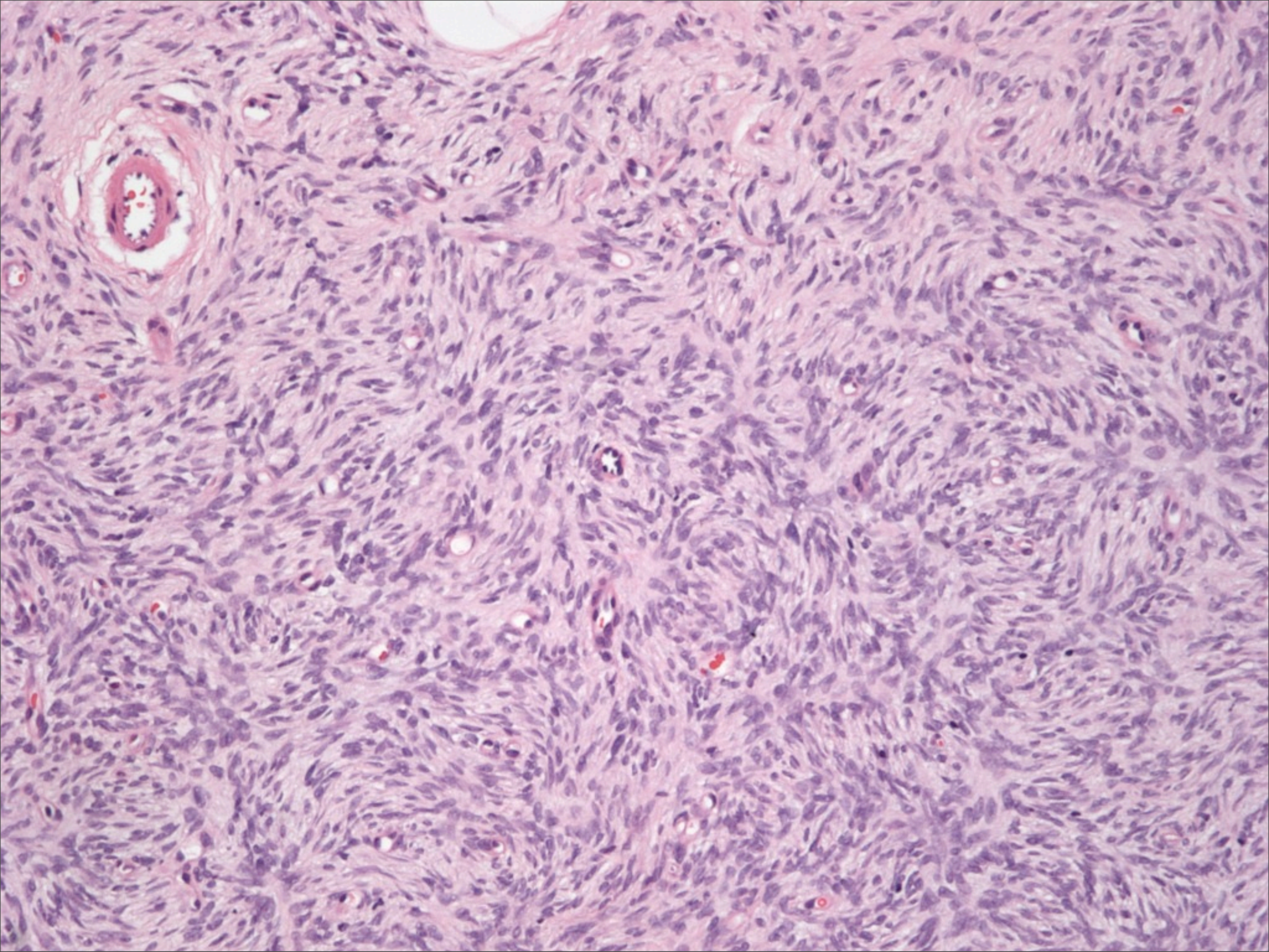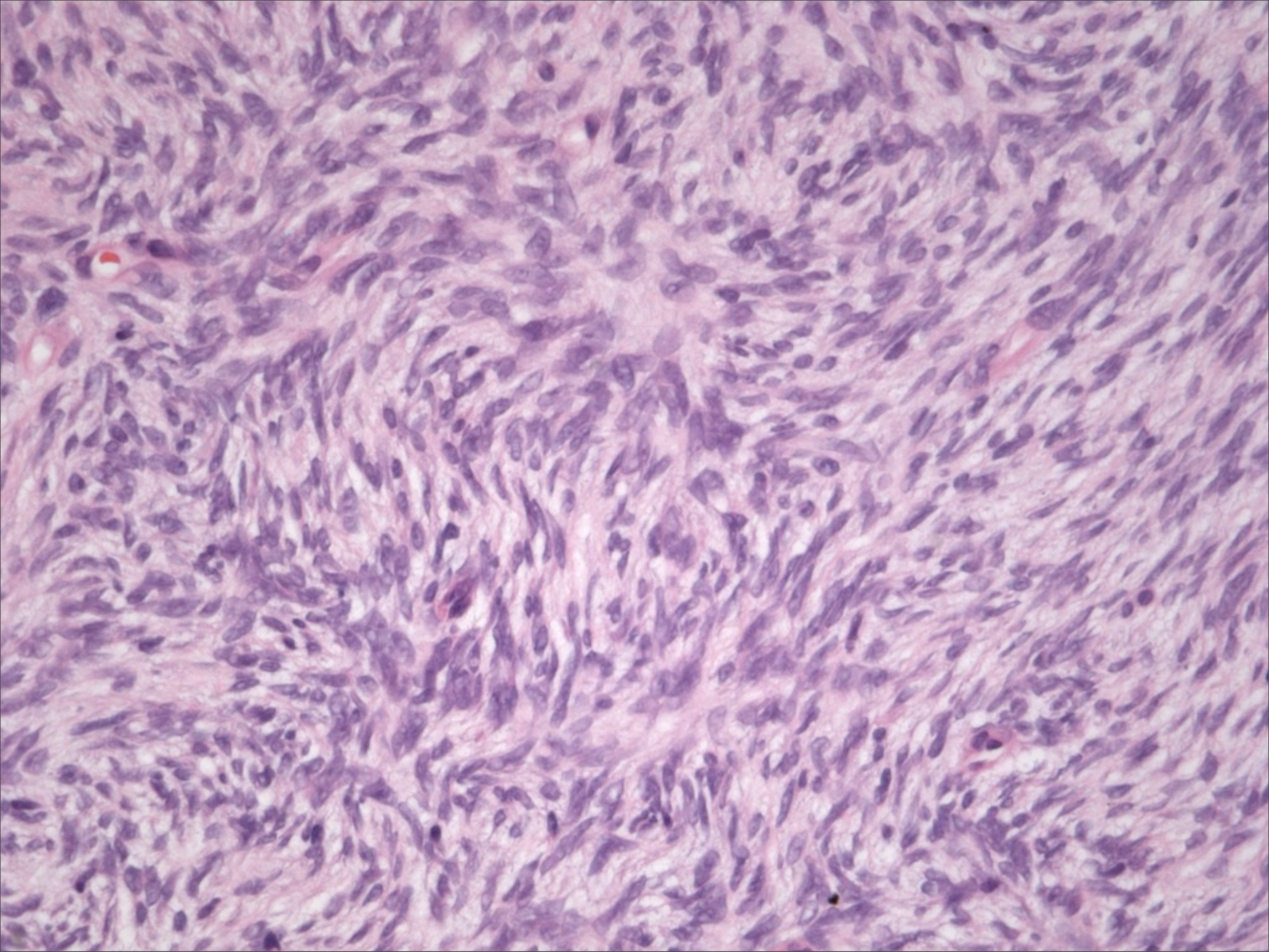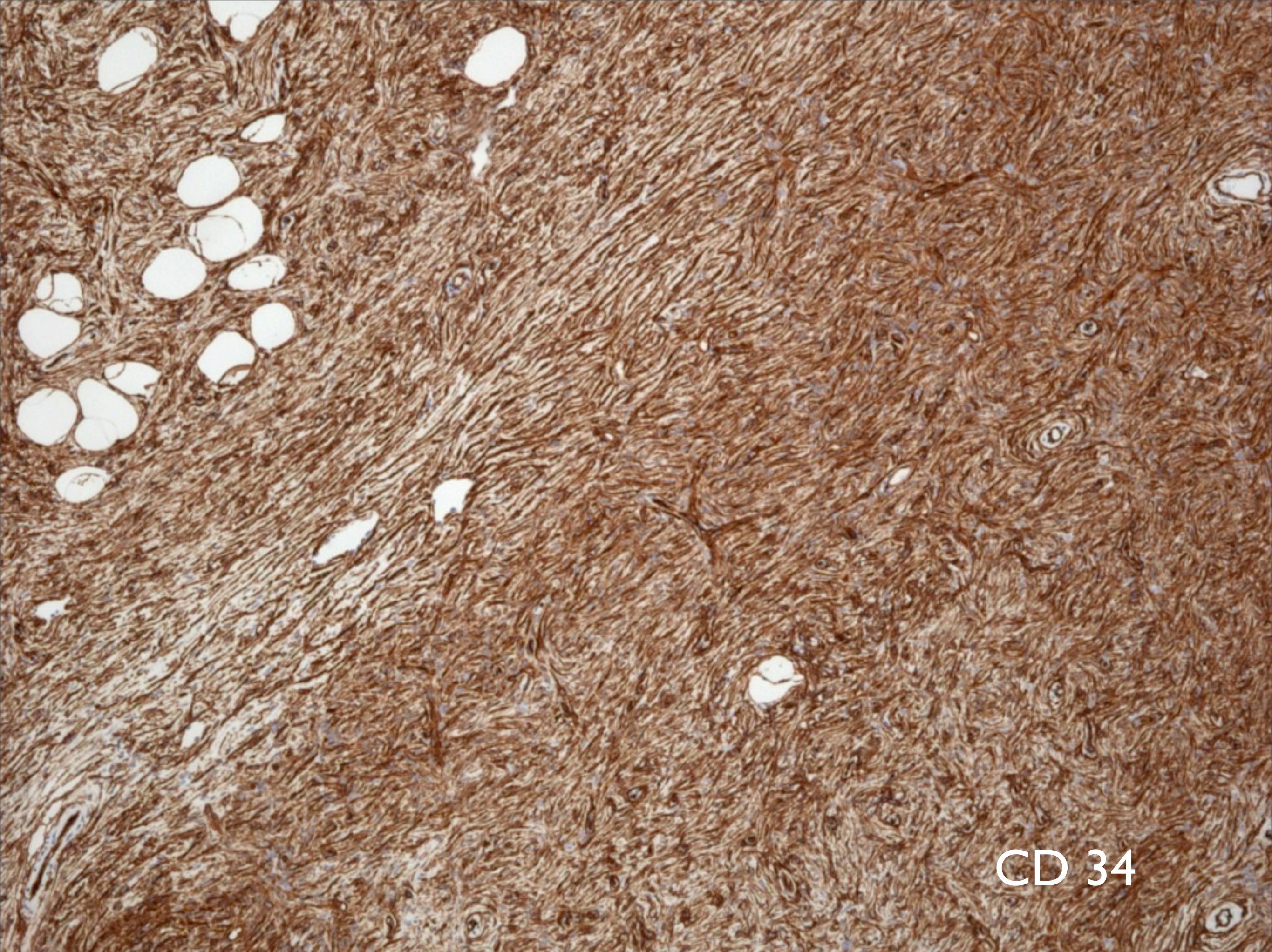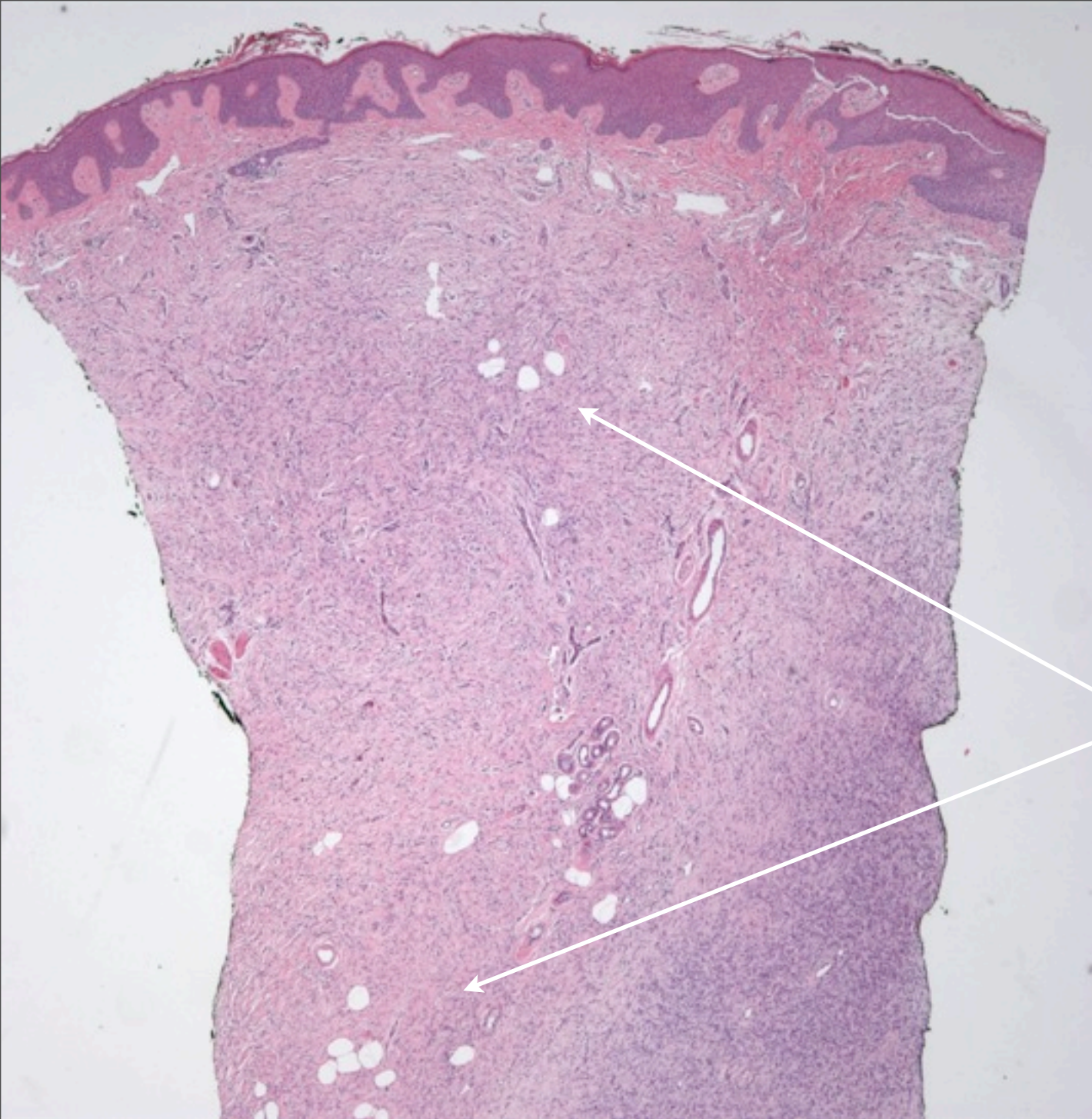


CD 34

Dermatofibrosarcoma Protuberans



Spindle cells in
storiform configuration

Adipocytes pulled into
papillary dermis with
“Swiss-cheese” pattern

Minimal Cytologic Atypia

Confirm with CD34 positivity